
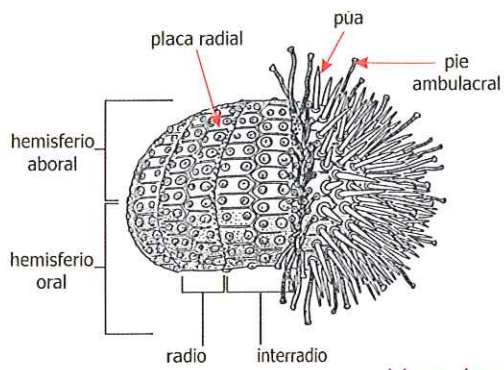


TÉRMINOS TÉCNICOS Y PRINCIPALES MEDIDAS UTILIZADAS

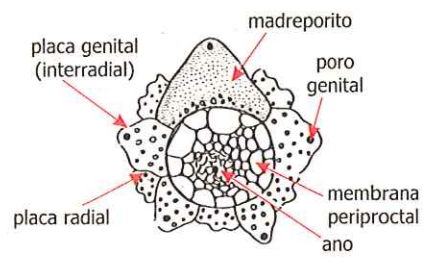
MORFOLOGÍA EXTERNA: ERIZOS



Vista lateral



Detalle hemisferio aboral



Vista dorsal

